

INTRODUCTION

- Ultrasound first described in 1950s, has since become more prevalent in medical practice
- Point-of-care (POC) ultrasound found to increase success of procedures, decrease complications, lower cost, increase patient satisfaction, and improve time to diagnosis
- Aim: To establish POC ultrasound education for residents to improve confidence and knowledge of ultrasound

METHODS

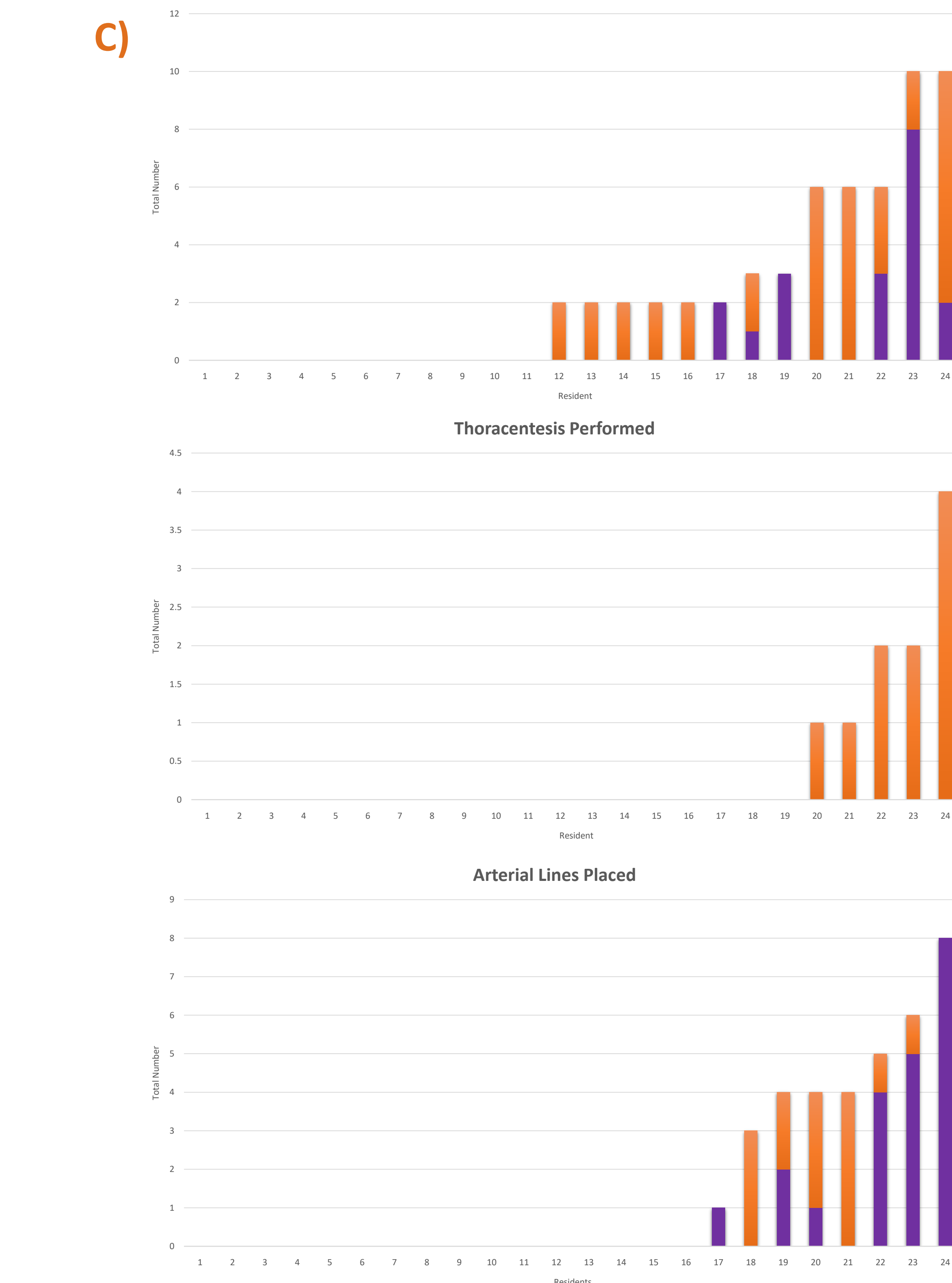
- ICU faculty with ultrasound experience enlisted as teacher
- Participants: Residents who rotated through ICU from August 2019 – February 2020
- Equipment used: Mindray TE7 ultrasound machines from Emergency and Radiology departments
- Teaching focused on internal jugular vein, radial artery, lung/pleura, and heart
- Pre- and post-course surveys used to evaluate confidence and knowledge
- Confidence measured using 5 point Likert scale (1 = strongly disagree to 5 = strongly agree)
- Knowledge measured with questions pertaining to ultrasound use for each body area taught

RESULTS

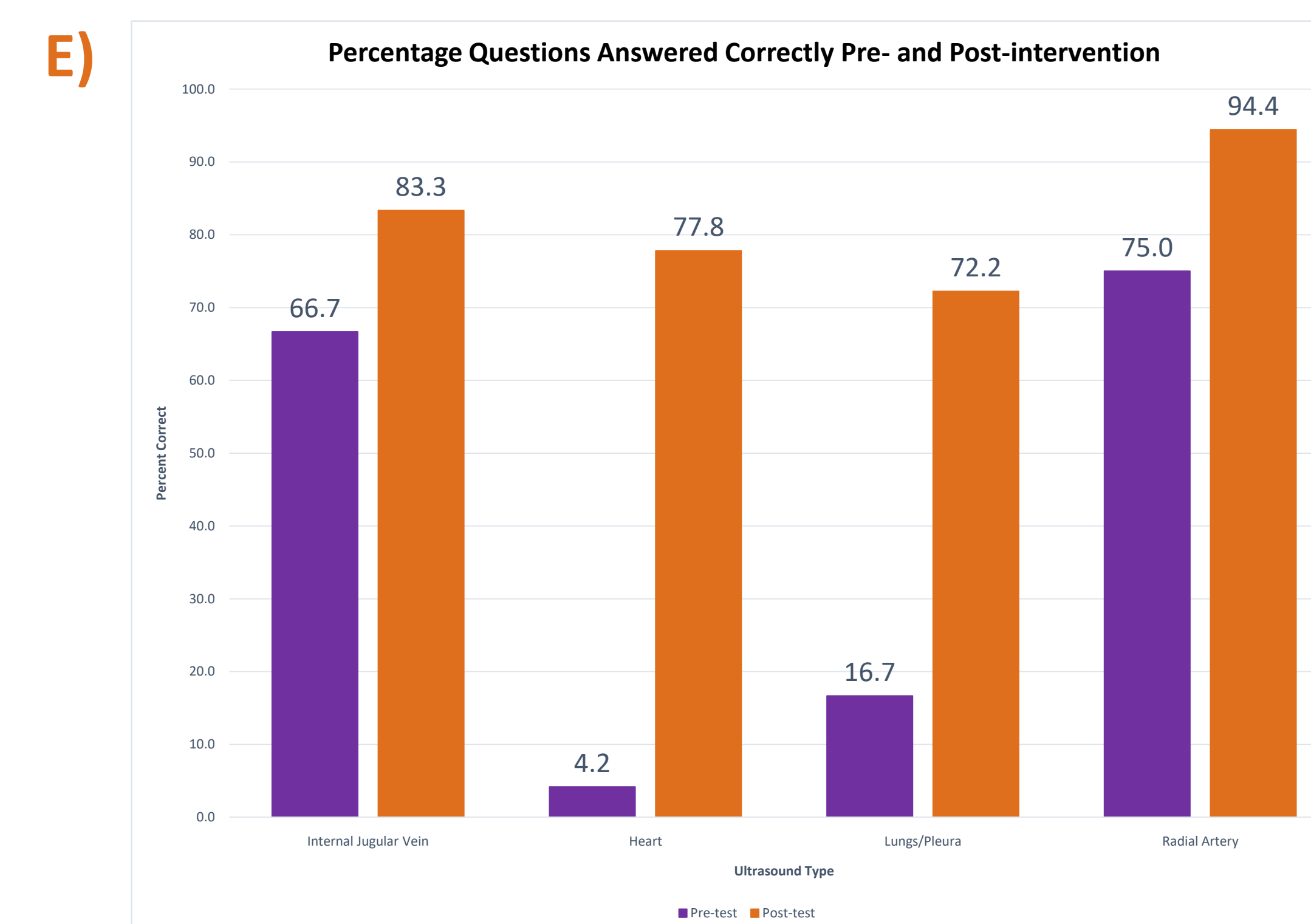
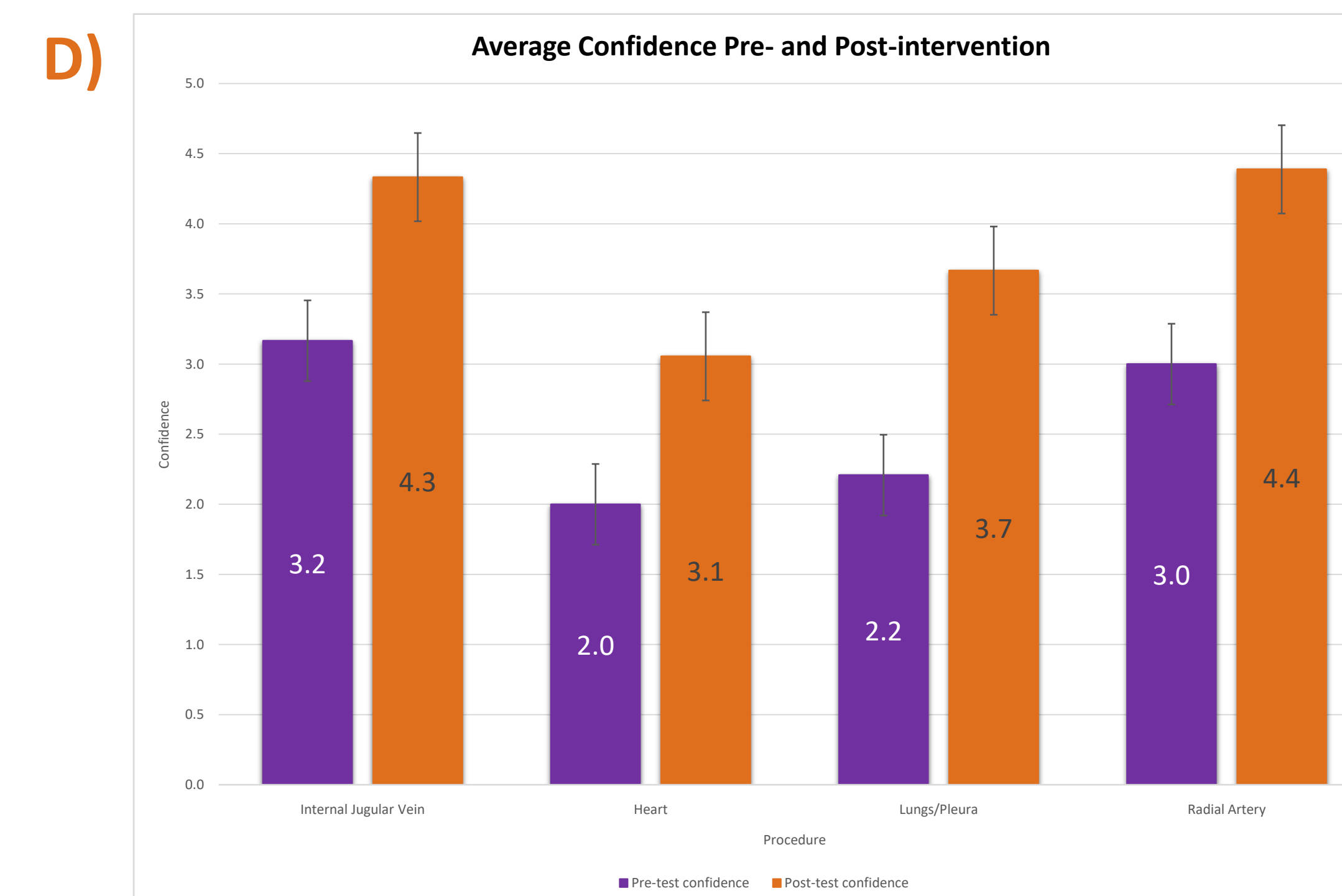
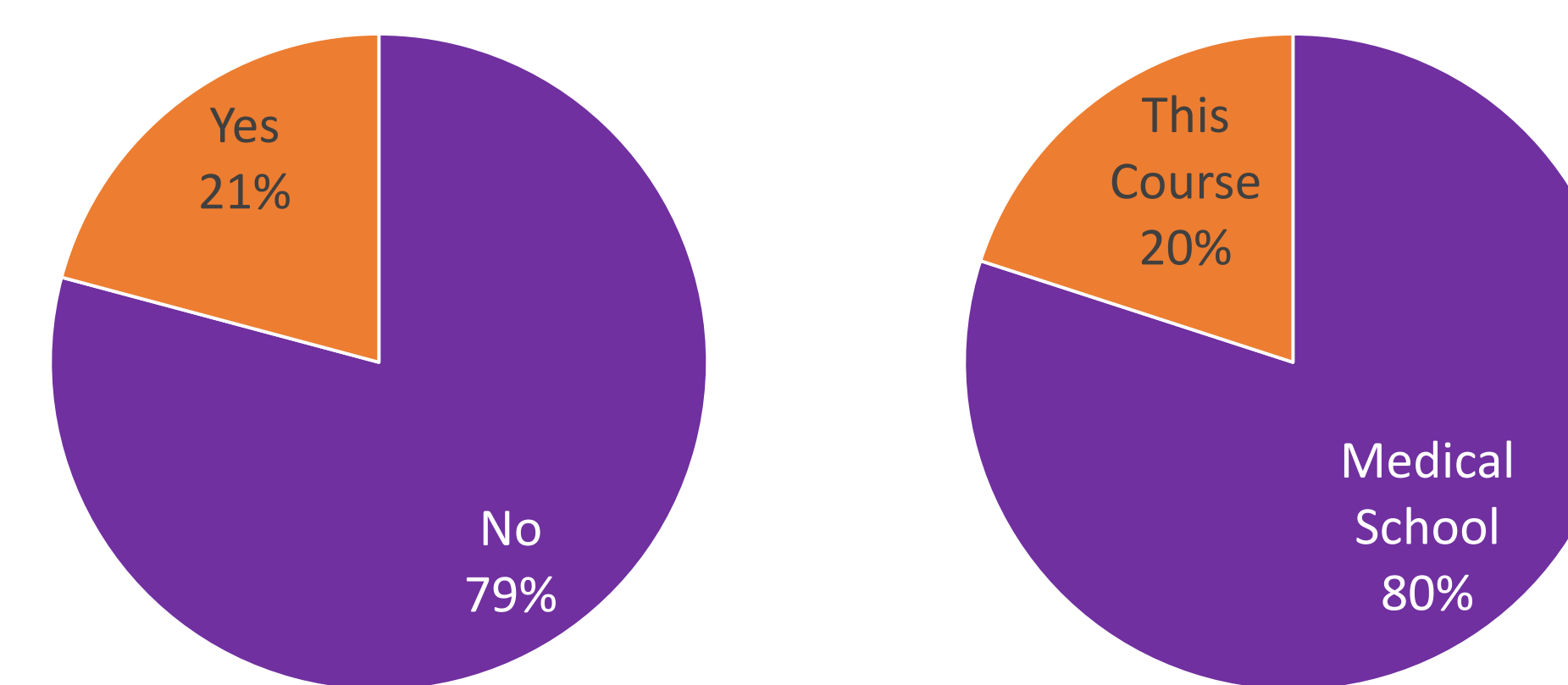
A) Survey for Ultrasound Teaching (Pre-survey)

PGY: _____

- Have you ever taken an Ultrasound course before? If so, where?
Yes No Where: _____
_____ # with ultrasound _____
- How many central lines have you placed? How many were done with ultrasound?
_____ # with ultrasound _____
- How many thoracentesis have you performed? How many were done with ultrasound?
_____ # with ultrasound _____
- How many arterial lines have you performed? How many were done with ultrasound?
_____ # with ultrasound _____
- Are you comfortable finding the internal jugular vein with ultrasound?
Strongly Disagree Disagree Neutral Agree Strongly Agree
- Are you comfortable finding the internal jugular vein with ultrasound?
Strongly Disagree Disagree Neutral Agree Strongly Agree
- Where is the carotid artery in relation to the internal jugular vein?
1.a) Where is the carotid artery in relation to the internal jugular vein?
2.a) Where do you place the probe for parasternal long and short axis views?
- Are you comfortable with performing ultrasound of the heart?
Strongly Disagree Disagree Neutral Agree Strongly Agree
- Are you comfortable with finding and identifying the pleura and pleural effusions?
Strongly Disagree Disagree Neutral Agree Strongly Agree
- What is the name of the white streaks in the lungs on ultrasound?
3.a) What is the name of the white streaks in the lungs on ultrasound?
- Are you comfortable with performing ultrasound of the radial artery with ultrasound?
Strongly Disagree Disagree Neutral Agree Strongly Agree
- What are characteristics to use for arteries on ultrasound?
4.a) What are characteristics to use for arteries on ultrasound?
- Having undergone the ultrasound session, what would you like to see to improve ultrasound education?
- Are you comfortable with identifying the radial artery with ultrasound?
Strongly Disagree Disagree Neutral Agree Strongly Agree
- What are characteristics to use for arteries on ultrasound?
8.a) What are characteristics to use for arteries on ultrasound?



B) Ultrasound Experience **Location of Previous Education**



- Legend:**
- A:** Pre- and post- course surveys and evaluations for residents.
 - B:** Participant experience with previous ultrasound education
 - C:** Number of procedures completed by participating residents and number of each procedure performed with ultrasound guidance. (Purple = procedures completed without ultrasound, orange = procedures completed with ultrasound)
 - D:** Comparison of resident confidence measurement pre- and post-course with standard error bars
 - E:** Comparison of number of correct answers from residents pre- and post-course

DISCUSSION

- Overall, residents appeared to have increase in confidence
- Overall, residents had improvement in number of questions answered correctly
- Residents allowed to leave comments: most comments positive about experience but commonly want more sessions
- Limited by anonymous surveys not allowing to follow personal change
- Limited by number of residents
- Possible expansion in future to encompass more uses for ultrasound and more organ systems
- Possible expansion to increase number of sessions/amount of exposure

References

Nazeer SR, Dewbre H, Miller AH. Ultrasound-assisted paracentesis performed by emergency physicians vs the traditional technique: a prospective, randomized study. *Am J Emerg Med.* 2005;23(3):363-367.

Patel PA, Ernst FR, Gunnarsson CL. Evaluation of hospital complications and costs associated with using ultrasound guidance during abdominal paracentesis procedures. *J Med Econ.* 2012;15(1):1-7. Epub 2011 Oct 19.

Dancel R, Schnobrich D, Nitin Puri, MD, Ricardo Franco-Sadud, MD, Joel Cho, MD, Loretta Grakis, MLS, Lucas BF, Mahmoud El-Barbary, MD, PhD, MSc, SHM Point of Care Ultrasound Task Force, and Niliam J. Sani, MD, MS, Recommendations on the Use of Ultrasound Guidance for Adult Thoracentesis: A Position Statement of the Society of Hospital Medicine. *J. Hosp. Med.* 2018;2:126-135. doi:10.12788/jhm.2940

Mitchell, D., Leng, A., Gardiner, S., Vanderwerff, L., Jones, S., Thompson, D., & Leng, P. (2016). Using Point-of-Care Bedside Ultrasound for Volume Assessment in Early Shock: An Outcome Study. *Chest, 149(4)*. doi:10.1016/j.chest.2016.02.154

Zanobetti, M., Poggioni, C., & Pini, R. (2011). Can Chest Ultrasonography Replace Standard Chest Radiography for Evaluation of Acute Dyspnea in the ED? *Chest, 139(5)*, 1140-1147. doi:10.1378/chest.10-0435

Practice Guidelines for Central Venous Access 2020: An Updated Report by the American Society of Anesthesiologists Task Force on Central Venous Access'. *Anesthesiology* 2020;132(1):8-43. doi: https://doi.org/10.1097/ALN.0000000000002864.